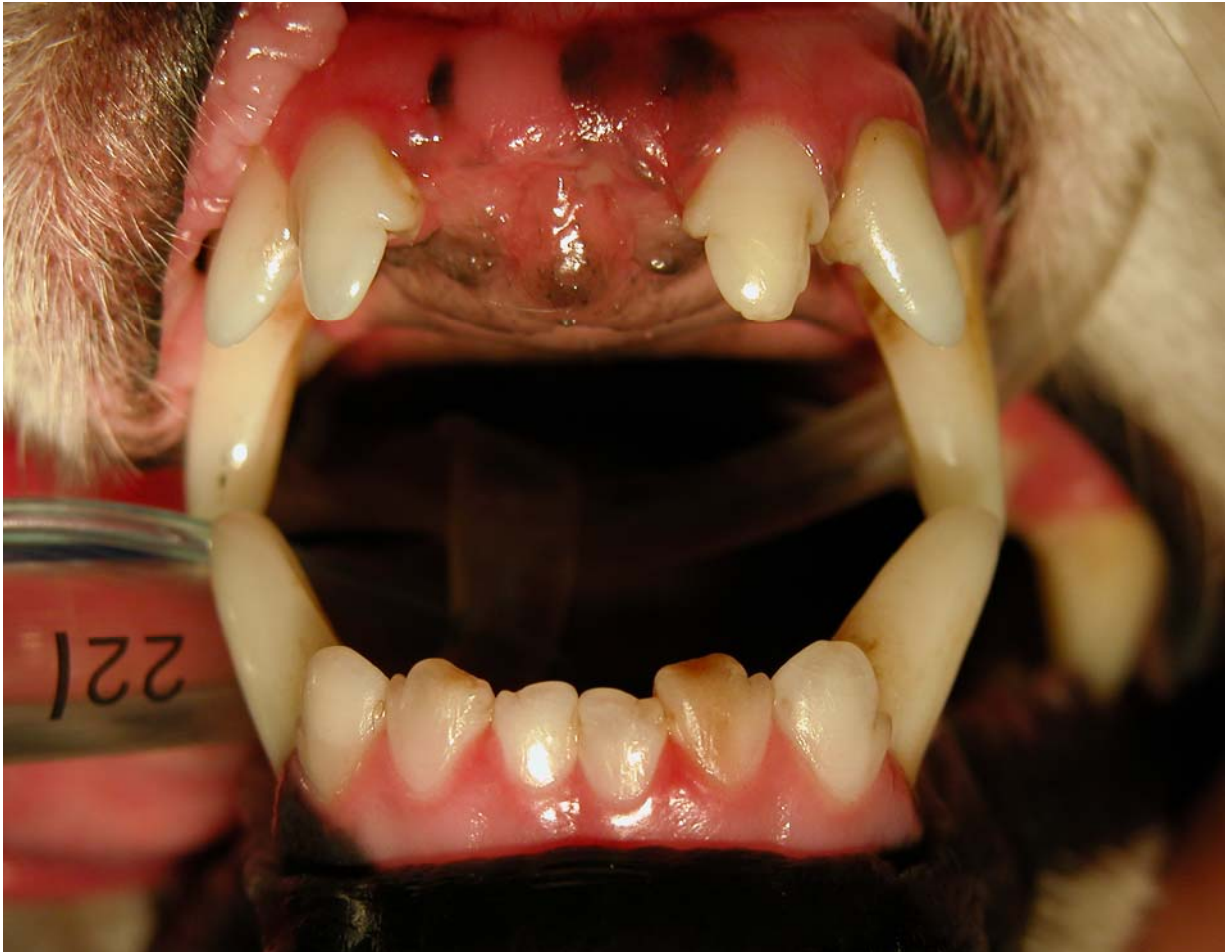

## Case of the Month

August 2007

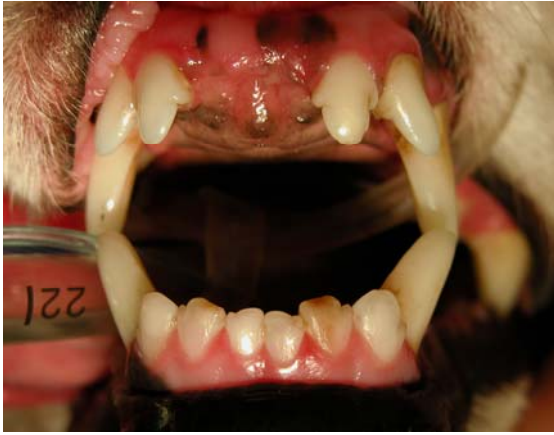### History and Signalment

A 7 year old miniature schnauzer presented for periodontal therapy. The dog ate dry dog food and was not having any problems according to the owner.



**Based on the photo above, what problems do you see and what is your plan?**

Veterinary Dental Center of Tulsa  
4820 E. 33<sup>rd</sup> Street  
Tulsa, OK 74135  
(918) 749-8387  
David S. Russell, DVM  
Fellow, Academy of Veterinary  
Dentistry

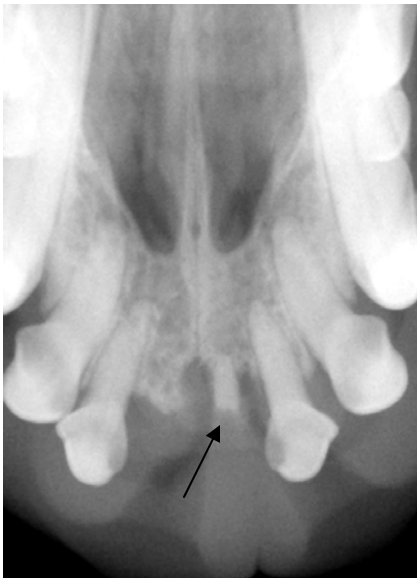


**Problems:**

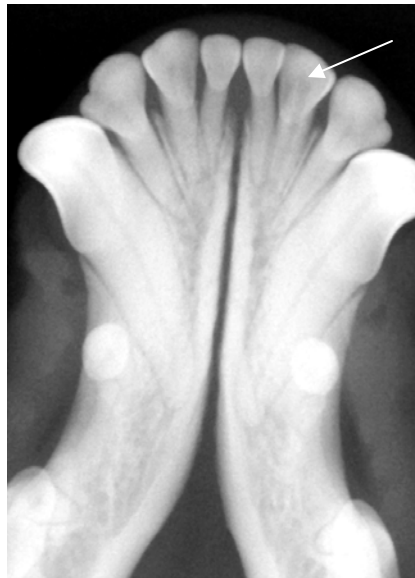Discolored mandibular left 2nd incisor  
Missing maxillary left and right 1st incisors

**Plan:**

Intraoral radiographs to check missing teeth and discolored incisor



A retained root is present causing maxillary bone loss.



The arrow points to the discolored incisor. The pulp chamber is wider than adjacent teeth indicating that it is most likely "dead."

**Treatment:**

The retained root was extracted. The mandibular incisor was also extracted, but a root canal could have been performed to save the tooth.. **A discolored tooth will almost always be dead or is dying and requires treatment.**

Veterinary Dental Center of Tulsa  
4820 E. 33<sup>rd</sup> Street  
Tulsa, OK 74135  
(918) 749-8387  
David S. Russell, DVM  
Fellow, Academy of Veterinary  
Dentistry