



**Veterinary Dental
Center of Tulsa**

Case of the Month February 2009

Signalment and History

12yr old cocker mix presented for a fractured maxillary right canine tooth (104) and a resorptive lesion at the mandibular right 2nd premolar tooth(406).

Oral Exam

Several teeth were missing. The canine tooth was fractured and granulation tissue was covering the fractured surface. Tooth resorption was found at the tooth 406 and the maxillary right 3rd premolar (107).

Full-mouth radiographs showed multiple teeth in various stages of root resorption. Tooth 104 was severely affected by tooth resorption which led to it's fracture.

Diagnosis and Treatment

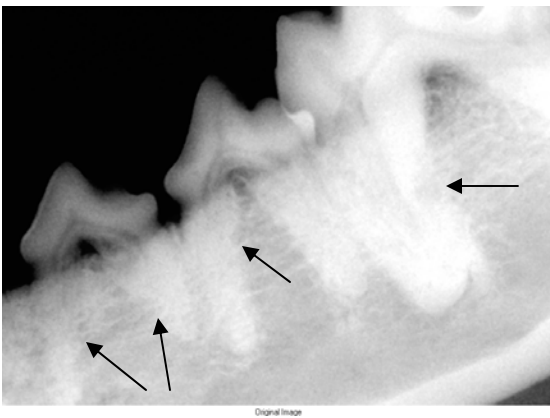
This dog was diagnosed with idiopathic root replacement resorption. Teeth 104, 107 and 406 required surgical extractions. The multiple other teeth that showed various stages of root resorption were not extracted. As long as the lesions are not exposed to the oral cavity, they are asymptomatic and do not require treatment. Teeth undergoing resorption are usually very difficult to extract. An oral examination and radiographs are recommended every 6-9 months.

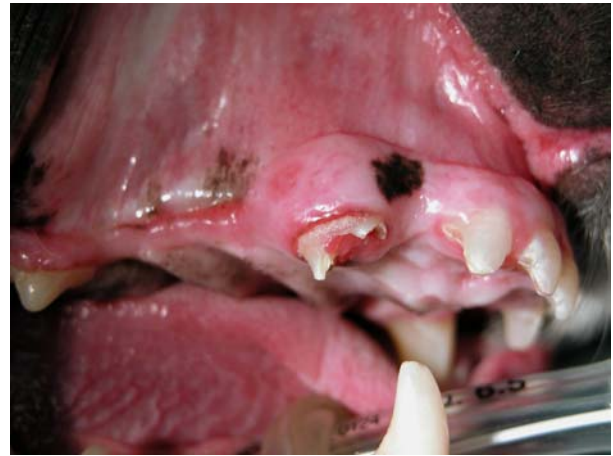
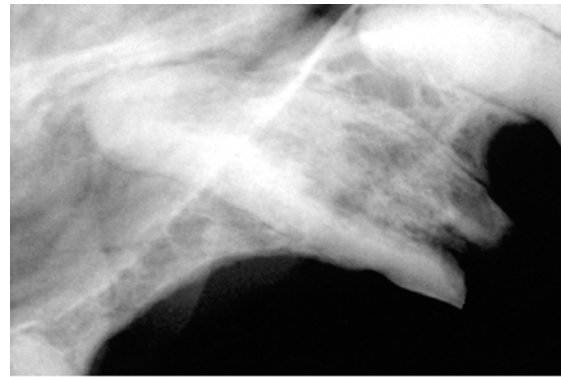
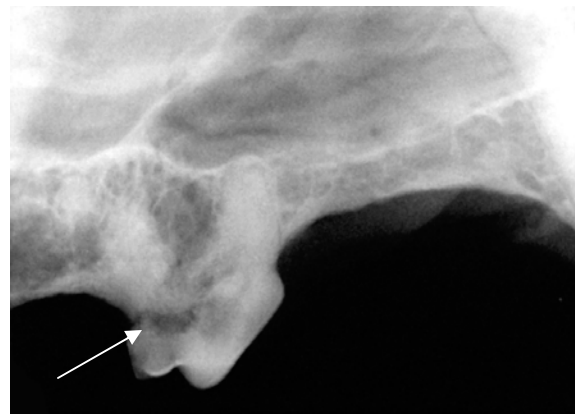Photo showing the fractured canine tooth.



Radiograph showing the severe resorption of the canine tooth.



Radiograph showing the multiple areas of tooth resorption.



Severe resorption of the maxillary right 3rd premolar.