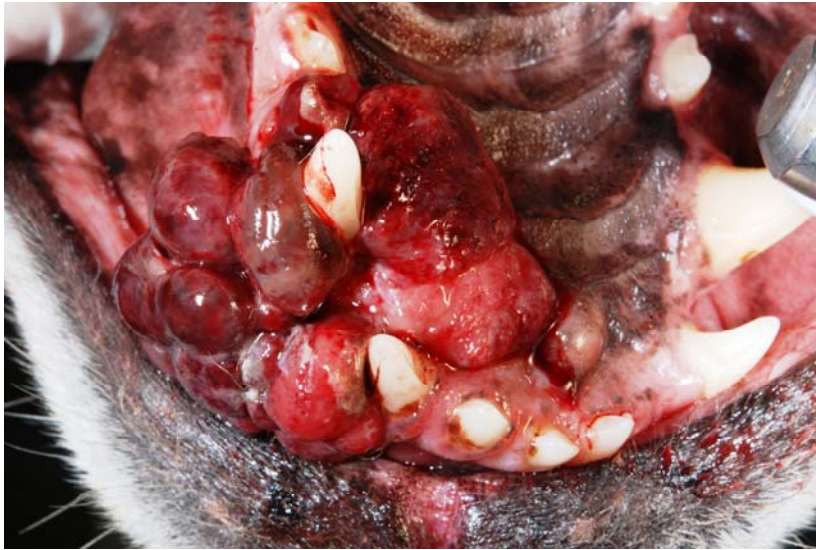
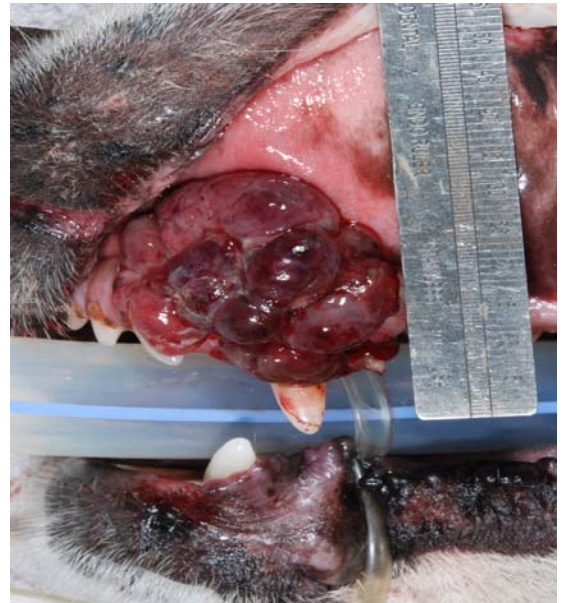
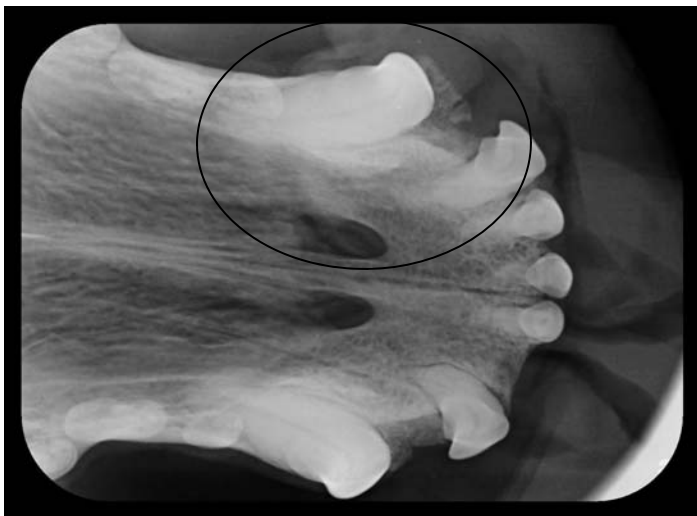
**Maxillary Osteosarcoma in a Dog**



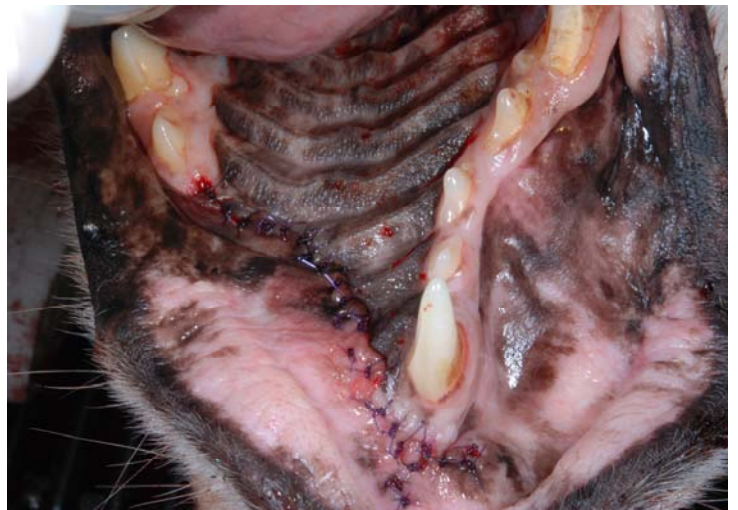Ventral view of the hard palate showing a large mass around the left canine tooth.



Lateral view of the maxillary mass.



The mass occupied the circled area on the radiograph.



A rostral maxillectomy was performed to excise the mass. The diagnosis was an osteosarcoma and the margins were clean.