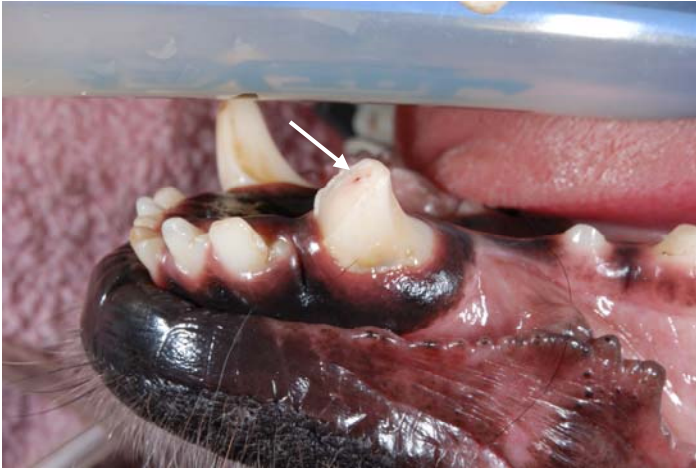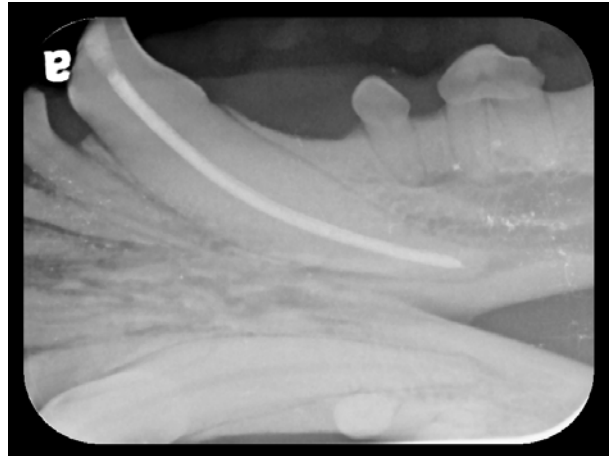


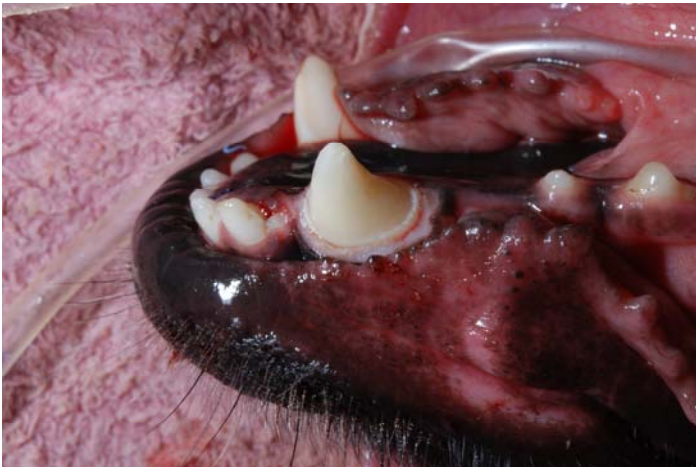Bruxzir™ Crown Restoration in a Dog



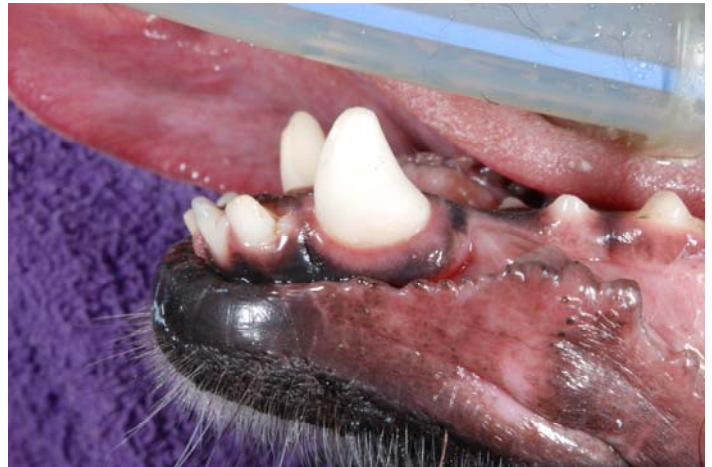A complicated crown-root fracture was found at the left mandibular canine tooth.



Root canal therapy was performed on the fractured tooth.



The tooth was prepped for a Bruxzir™ crown.



The Bruxzir™ crown was cemented to the tooth.

Some clients will decline metal crown therapy for esthetic reasons. Tooth-colored porcelain has been an option, but it can easily be chipped or cracked. Bruxzir™ crowns are made from medical-grade zirconia. The material is virtually unbreakable and biocompatible and can be made to match the color of the existing teeth. The company claims that it can be used on 4th premolars and military/police dogs.